



PATIENT

Haboob Borland

SPECIES

Feline

BREED

DSH

SEX

Female Spayed

AGE

16 years

WEIGHT

5.0kgs

INTERPRETED BY

Maggie Machen Lamy,
DVM, DACVIM
(Cardiology)

IMAGING PERFORMED BY

Nigel Gumley, DVM

HOSPITAL NAME

Cedarview Animal
Hospital

REFERRING VET

Dr. Gumley

INVOICE

22798

DATE

2/24/22

PRESENTING CLINICAL SIGNS

History: Irregular cardiac rhythm - VPCs noted on ECG. Diagnosed with CKD last year and managed with renal diet. Chronic borderline high T4. BP: 120/95, 145/65, 130/55, 155/80mmHg. Skipped beats on auscultation, no syncope, lung fields normal, no respiratory signs.

ECHOCARDIOGRAM FINDINGS

2D, m-mode, color flow and doppler imaging is available. The left ventricular wall is borderline normal in dimension. There is a diffusely hyperechoic endocardium consistent with fibrosis. The endocardium also appears remodeled. Remodeled papillary muscles. The left atrium is normal. The mitral valve is normal in structure and mobility. No MR. The right atrium is normal. The right ventricle appears normal. No TR. Blood flow through both the LVOT and RVOT is normal in velocity. No PI or AI. No effusions or obvious cardiac tumors identified. VPCs noted throughout (single-lead ECG attached).

CARDIAC CHART

FELINE CARDIAC PARAMETERS	BODY WEIGHT (kg)	HR (BPM)	IVSd (cm) (Moise, Pipers)	LVIDd (cm) (Moise, Pipers)	LWVd (cm) (Moise, Pipers)	FS (%)	EF (%)
NORMAL PARAMETER	-----	150-240	0.35-0.55	<2 (mean 1.5)	3.5-0.55	35-67	80-100
PATIENT	5.0	164	0.55	1.2	0.57	53	88
FELINE CARDIAC PARAMETERS	LA/AO (Boon)	LA/AO HEART BASE (Swe) (Abbott)	LA 2D short axis Base view (cm) (Abbott)		LVOT VEL (m/s)	RVOT VEL (m/s)	E max (m/s)
NORMAL	<1.5	<1.3	<1.2		<1.6	<1.3	<0.9
PATIENT	1.4	1.3	1.2		1.2	0.8	NM
<p><i>*Note: All measurements based upon multi-modal images and methods. An average value is reported.</i> Adapted from June Boon, Veterinary Echocardiography, 1998 Abbott J & MacLean H JVIM 2006;20: 111-119, Moise et al. Am J Vet Res 47:1476, 1986. Pipers et al. Am J Vet Res 40:882, 1979.</p>							

INTERPRETATION OF THE FINDINGS & FURTHER RECOMMENDATIONS

Overtly normal geriatric cardiac structure and function is identified in this study. The LV walls are borderline in dimension which may suggest early hypertrophic disease or may simply be a normal variant. Additionally, the LV is quite remodeled and irregular which may be indicative of early cardiac disease or may simply represent a normal variant. Serial echocardiography will be necessary to determine progression. Regardless, no additional issues are identified, and the LA dimension is normal.

Presumably a fibrotic LV is enough to cause VPCs; however, systemic/extra-cardiac causes should be considered in a senior cat. Full systemic evaluation may be reasonable. Follow up/treatment should be dictated based upon the ECG report.



PATIENT

Haboob Borland

From a structural standpoint, no contraindication for general anesthesia. The VPCs are a separate issue, and the ECG report should dictate protocol. Judicious IV fluid rates are advised to avoid fluid overload.

SPECIES

Feline

Monitor for any development of clinical signs at home, including labored breathing, cough or signs of a blood clot (paralysis, neurologic change).

BREED

DSH

No cardiac medications are clearly indicated.

SEX

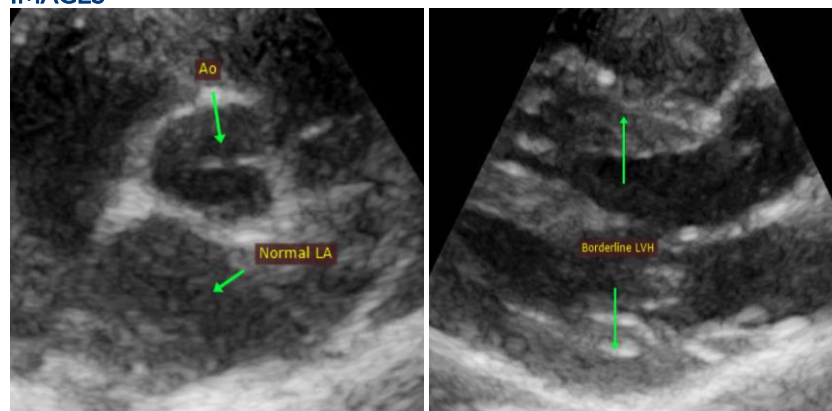
Female Spayed

A recheck echocardiogram and ECG are recommended in 6-12 months to screen for progressive changes.

AGE

16 years

IMAGES



WEIGHT

5.0kgs

INTERPRETED BY

Maggie Machen Lamy,
DVM, DACVIM
(Cardiology)

The information and recommendations provided are based on the images presented by the referring veterinarian. No evaluation can be communicated regarding pathology that was not visible in the image/video clips provided.

IMAGING PERFORMED BY

Nigel Gumley, DVM

Thank you for this referral. This report was generated using transcription software, and minor dictation errors may be present. If the clinical or image interpretation does not parallel your findings or if I can be of any further assistance, please contact me.

HOSPITAL NAME

Cedarview Animal
Hospital

Maggie Machen Lamy, DVM
Diplomate of the American College of Veterinary Internal Medicine (Cardiology)
info@sonopath.com

REFERRING VET

Dr. Gumley

INVOICE

22798

DATE

2/24/22